

Wolff-Parkinson-White Syndrome in a Young Athlete

Brendan Saunders¹ • Miriam Matthews¹ • Lynnette Mazur, MD, MPH² • Moutaz El Kadri, MD, MSc, PhD³

A 13-year-old boy presented with his parents to his general practitioner with a skipping heartbeat, shortness of breath, dizziness, and chest pressure. He was an athlete and had experienced 4 such episodes in 7 months—3 had occurred during physical exertion and 1 at rest. These episodes were described as an “unsteadiness in the heart,” beginning with a few seconds of an irregular rhythm followed by 1 to 2 minutes of a speeding heartbeat. Each episode had lasted approximately 5 minutes, causing him to feel exhausted and dizzy.

He denied syncope and consumption of caffeinated beverages. There was no family history of heart disease or sudden death. The differential diagnosis included cardiac, endocrine, and pulmonary disorders and recreational drug use (Table 1).

An electrocardiography (ECG, Figure 1) scan revealed the presence of a delta wave, a prolonged QRS interval of 150 ms (abnormal reference range, > 120 ms),

TABLE 1. DIFFERENTIAL DIAGNOSIS OF PALPITATIONS IN ADOLESCENTS

Recreational drug-induced tachycardia	Tachycardia can be induced by recreational drugs such as cocaine, methamphetamines, LSD, and even caffeinated energy drinks.
Supraventricular tachycardias	Atrial fibrillation, atrial flutter, and atrial tachycardia can cause symptoms of palpitations, dizziness, and chest discomfort.
Ventricular tachycardia	Includes ventricular fibrillation and ventricular tachycardia; they are responsible for most sudden cardiac deaths.
Hypertrophic obstructive cardiomyopathy (HOCM)	HOCM can present with palpitations, shortness of breath, and chest pain.
Endocrine disorders	Hyperthyroidism and pheochromocytomas can induce tachycardia.
Rheumatic heart disease	Valvular heart diseases such as mitral stenosis and mitral regurgitation can present with palpitations and chest discomfort.
Pulmonary embolism	Pulmonary embolisms can present in youth with hypercoagulability syndromes or illicit use of testosterone.

and a shortened PR interval of 110 ms (abnormal reference range, < 120 ms)¹, which fulfilled the criteria for Wolff-Parkinson-White (WPW) syndrome. The patient was referred to a cardiologist, where a treadmill stress test was conducted to assess the refractory period of the accessory pathway. The test requires patients to walk or run at progressively faster and steeper gradients. Each stage lasts 3 minutes, and total duration is adjusted to the patient’s tolerance.² A 12-lead ECG was connected for the duration of the test. The delta wave persisted during the test, and no arrhythmia was induced. Results of a 24-hour Holter monitor and an echocardiography scan were normal.

AFFILIATIONS:

- ¹University College Dublin, Dublin, Ireland
- ²John P. and Kathrine G. McGovern Medical School, University of Texas, Houston
- ³Sheikh Shakhbout Medical City, Abu Dhabi, United Arab Emirates

CITATION:

Saunders B, Matthews M, Mazur L, El Kadri M. Wolff-Parkinson-White syndrome in a young athlete. *Consultant*. Published online November 19, 2021. doi:10.25270/con.2021.11.00011

ACKNOWLEDGMENTS:

Brendan Saunders and Miriam Matthews contributed equally to this article.

DISCLOSURES:

The authors report no relevant financial relationships.

CORRESPONDENCE:

Lynnette Mazur, MD, MPH, John P. and Kathrine G. McGovern Medical School, University of Texas, Houston, 6410 Fannin Street #1014, Houston, TX 77030 (Lynnette.j.mazur@uth.tmc.edu)

The cardiologist recommended discontinuing vigorous exercise and initiating a β -blocker agent. However, the patient and his parents were hesitant to start a β -blocker agent, as this would interfere with his athletic endeavors.

One month later, at a follow-up visit, an electrophysiologic study (EPS) was conducted, results of which revealed a left anterolateral accessory pathway. At this time catheter ablation was performed, and repeat ECGs returned normal results (Figure 2). The patient had no further symptoms.

Discussion

WPW syndrome is a congenital electrical abnormality of the heart typically associated with supraventricular tachycardia.¹ It is caused by an extra, accessory atrioventricular conduction pathway in which impulses get caught in a circular conduction pattern, travelling around the heart at an increased rate. Symptoms of tachycardia include palpitations, dizziness, fatigue, shortness of breath, and loss of consciousness.³ In rare cases, WPW can lead to sudden cardiac death presumably because of ventricular fibrillation.¹

WPW was first described by Wolff, Parkinson, and White in 1930 as "the occurrence of bundle-branch block curves in healthy young adults and children."⁴ The definition has since evolved, as the electrophysiological understanding of pre-excitation has increased; it is no longer considered a bundle-branch block but rather a pre-excitation abnormality.⁵ Pre-excitation refers to the premature activation of part or all of the ventricle caused by transmission of an impulse along an accessory pathway that is not subject to normal atrioventricular node delay.¹

WPW affects an estimated 1.5 to 3.1 per 1000 persons in Western countries or 0.1% to 0.3% of the total population.^{3,6} It is more common in men and can present at any age, but patients younger than age 35 years are at higher risk.¹ WPW is diagnosed via an ECG with characteris-

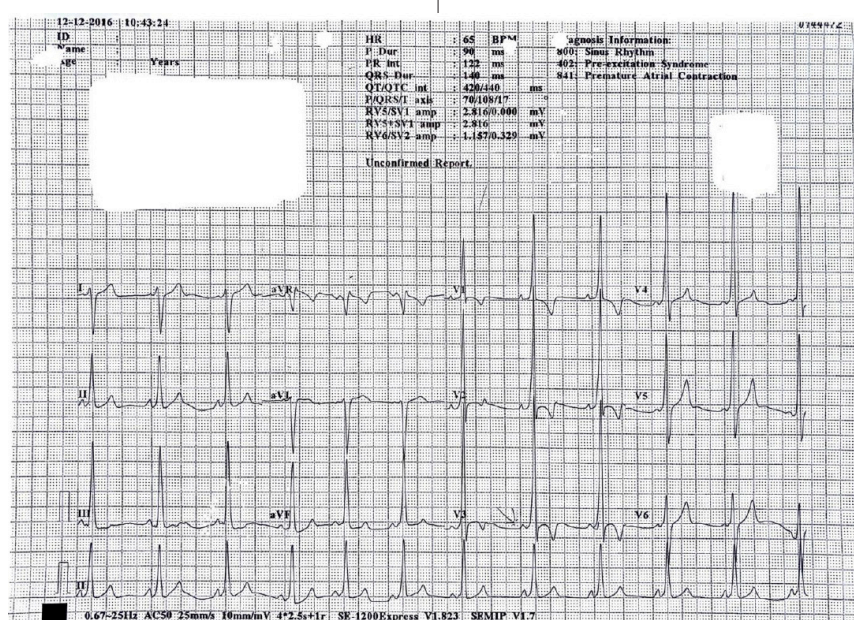


Figure 1. An ECG revealed the presence of a delta wave, a prolonged QRS interval, and a shortened PR interval.

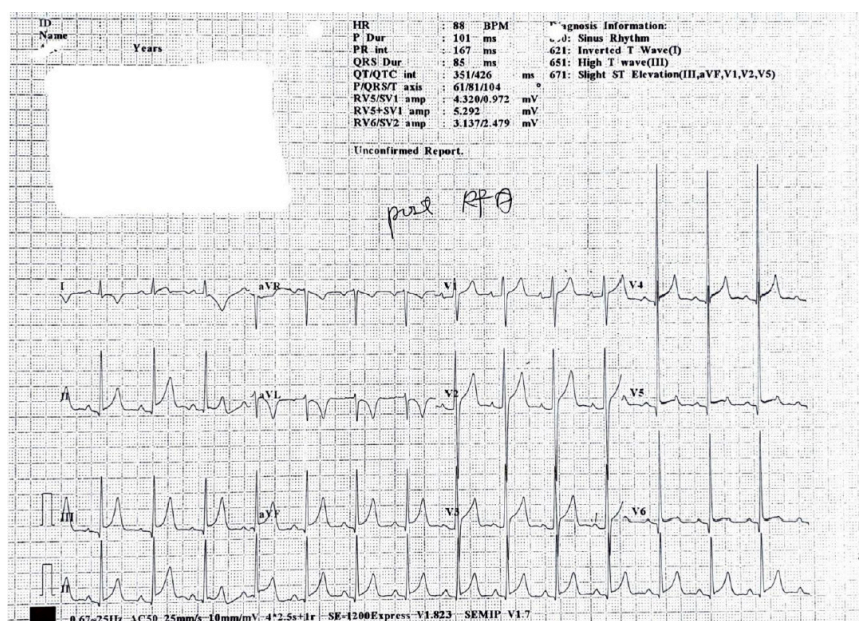


Figure 2. A repeat ECG showed normal results after a catheter ablation was performed.

tic findings of a slurred upstroke (delta wave) on a widened QRS complex and a shortened PR interval. Patients with WPW "syndrome" have both an identified manifest on an ECG and a symptomatic arrhythmia; patients with WPW "pattern" have ECG abnormalities without

symptoms.¹ It is estimated that 65% of adolescents and 40% of adults aged older than 30 years with WPW have the "pattern" subtype.¹

Estimates of the prevalence of the asymptomatic, WPW pattern in children are unclear, as a majority of the ECG scans

CASE IN POINT

are in adults and suggest a prevalence between 0.1% and 0.3%.⁵ In children, it is thought that the prevalence is higher: In a study of 446 patients with WPW diagnosed in childhood, 84.0% were symptomatic (WPW syndrome), and sudden cardiac death had occurred in 1.3% (6 of 446) patients.⁷

Diagnostic testing

The approximate location of an accessory pathway can first be identified non-invasively by ECG. In a study of 100 children with WPW syndrome, researchers examined the accuracy of electrocardiographic algorithms to localize the accessory pathway.⁸ Seven common algorithms were tested, each using distinct criteria to assess QRS and delta wave polarity and the R/S ratio. However, they found that all 7 algorithms were significantly less accurate in children than in adults; precise pathway location was identified only in 34.0% to 49.0% of children.⁸ One pediatric algorithm, with a 90% accuracy rate, accounts for electrocardiographic differences found in accessory pathways in children.⁹

Atrioventricular reciprocating tachycardia (AVRT) is a type of supraventricular tachycardia associated with WPW syndrome. AVRT can be orthodromic, following the normal physiological route, or antidromic when the depolarization wave follows the opposite route of physiologic conduction.¹⁰ Orthodromic AVRT involves antegrade conduction through

the atrioventricular node and retrograde conduction through the accessory pathway, whereas antidromic AVRT involves antegrade conduction through the accessory pathway and retrograde conduction through the atrioventricular node. Up to 90% of patients with WPW syndrome are orthodromic and manifest with narrow QRS complexes.¹⁰ Patients with a concealed accessory pathway with retrograde conduction have an unremarkable ECG and no pre-excitation.¹¹ Antidromic AVRT is less common and is associated with a wide QRS complex.¹

Sudden cardiac death is the concern for patients with both symptomatic and asymptomatic WPW. The risk in children is unclear because of the absence of pediatric screenings for WPW. However, the overall risk in children may be greater than in adults. A study conducted in Italy that included 550 asymptomatic adults and children with WPW over 8 years showed that 13 (2.4%) had developed ventricular fibrillation, 11 of whom were children.¹² Additionally, WPW accounts for at least 1.0% of sudden cardiac death in asymptomatic athletes.¹³

In a study of EPSs in 10 patients with WPW syndrome, the rate of atrioventricular conduction via the accessory pathway was greater during exercise than at rest (mean increase of 28%).¹⁴ Three patients had a ventricular rate exceeding 300 beats/min. Adrenaline facilitates conduction in accessory pathways, resulting in the appearance of delta waves

during stress despite their intermittent presence at rest.³ This exercise-induced enhancement of the accessory pathway may increase the risks of sudden death for athletes with WPW and consequently influence treatment. Pediatric patients, boys, and athletes are among those more likely to become symptomatic and need further evaluation.

Because of the small but serious risk of sudden cardiac death in patients with WPW pattern, risk stratification is recommended. Initial testing is noninvasive and can include ambulatory ECG monitoring, a treadmill stress test, and an echocardiography scan, which may identify structural heart abnormalities such as Ebstein anomaly or hypertrophic cardiomyopathy.¹³ Noninvasive testing may characterize the accessory pathway if there is a sudden disappearance of the delta wave, indicating a low-risk pathway.¹³ However, if pre-excitation or a delta wave persists during a stress test at higher heart rates, invasive testing (such as an EPS) is recommended. An EPS can better characterize an accessory pathway, and radiofrequency catheter ablation can be performed during the study, as was the case with our patient.¹⁴

Other risks associated with WPW include the development of reentrant tachycardias (15%-25% of asymptomatic patients).⁵ The presence of an accessory pathway is also associated with the development of atrial fibrillation later in life. Ventricular pre-excitation may lead to dilated cardiomyopathy secondary to dyssynchronous ventricular contraction in rare cases.⁵

Treatment

Treatment of WPW includes both pharmacological and procedural options (Table 2). Currently, catheter ablation, which involves inserting a catheter into the right femoral vein and using radiofrequency energy to ablate accessory pathways, is the treatment of choice; it has an overall long-term success rate of 95%.¹⁵ It also avoids long-term medical therapy.^{13,15}

However, long-term pharmacological

TABLE 2. TREATMENT OPTIONS FOR WOLFF-PARKINSON-WHITE SYNDROME AND PATTERN

Acute treatment of symptomatic WPW	Nonmedical therapy	Valsalva maneuver
		Carotid sinus massage
	Pharmacological therapy (AV nodal-blocking agents)	Adenosine
Treatment of recurrent arrhythmias in WPW	Procedural therapy	Verapamil
		Procainamide or β -blockers
		Catheter ablation (preferred)

options remain an alternative for patients with pathways too close to the bundle of His or for patients refusing ablation. With pharmacological treatment, it is crucial to recognize WPW and the type of arrhythmia, because mistreatment can be fatal. In cases where antidromic AVRT or atrial fibrillation is present, the use of atrioventricle-blocking agents such as amiodarone, β -blockers, calcium channel blockers, and digoxin (ie, ABCD treatment) are contraindicated because conduction may be favored through the accessory pathway, causing lethal ventricular dysrhythmias (ie, ventricular fibrillation) or hemodynamic instability.¹ No medications are contraindicated for patients with orthodromic AVRT. Pharmacological treatment for athletes with WPW (with antiarrhythmic medications) are a less-ideal option because they impair athletic performance and can cause respiratory distress and emotional lability. Additionally, γ -adrenergic blocker agents are banned in competitive archery and riflery.³ Catecholamines released during exercise may also suppress the effects of antiarrhythmic agents.³ Therefore, catheter ablation is preferred.

The treatment of WPW pattern is controversial in children because many remain asymptomatic for their entire life.⁵ Furthermore, resolution of manifest pre-excitation occurs in about 35.0% of children aged 3 months or younger and has been reported in children up to age 12 years, particularly in the presence of a long refractory period of the accessory pathway.^{7,16} However, the risk of sudden cardiac death must be taken seriously.

In asymptomatic athletes, the treatment is dependent on lifestyle.¹ EPS is recommended for athletes who perform at a moderate or high level of activity.³ Because of the lack of reliability of risk-stratification tools, most pediatric electrophysiologists now recommend proceeding with a low threshold for default ablation of all accessory pathways distant from critical conduction structures because of the higher risk of sudden death in children and athletes.⁵

For athletes and children with WPW syndrome, early treatment is recommended. In patients with multiple accessory pathways or a ventricular rate exceeding 240 beats/min, catheter ablation is always recommended.^{3,17}

Conclusion

Pediatric WPW is manageable and treatable. Currently, catheter ablation is the treatment of choice for most young patients and athletes with recurrent supraventricular tachycardia. However, long-term pharmacological options remain an alternative for patients with pathways too close to the bundle of His or for patients refusing ablation. Patients need to understand the treatment options and their associated benefits and risks to make an informed decision, since treatment relates to their lifestyle.

Further research on screening pediatric patients and athletes is needed because of the increased risk of sudden cardiac death.

REFERENCES

1. Chhabra L, Goyal A, Benham MD. Wolff Parkinson White Syndrome. In: *StatPearls*. StatPearls Publishing; August 11, 2021. <http://www.ncbi.nlm.nih.gov/books/nbk554437/>
2. Vilcant V, Zeltser R. Treadmill Stress Testing. In: *StatPearls*. StatPearls Publishing; October 11, 2021. <http://www.ncbi.nlm.nih.gov/books/nbk499903/>
3. Saxena A, Chang CJ, Wang S. Wolff-Parkinson-White syndrome in athletes. *Curr Sports Med Rep*. 2006;5(5):254-257. <https://doi.org/10.1097/01.csmr.0000306424.31661.a6>
4. Wolff L, Parkinson J, White P. Bundle-branch block with short P-R interval in healthy young people prone to paroxysmal tachycardia. *Am Heart J*. 1930;5(6):685-704. <https://doi.org/10.1111/j.1542-474x.2006.00127.x>
5. Chubb H, Ceresnak SR. A proposed approach to the asymptomatic pediatric patient with Wolff-Parkinson-White pattern. *HeartRhythm Case Rep*. 2020;6(1):2-7. <https://doi.org/10.1016/j.hrcr.2019.09.003>
6. Gollob MH, Green MS, Tang AS, et al. Identification of a gene responsible for familial Wolff-Parkinson-White syndrome. *N Engl J Med*. 2001;344(24):1823-1831. <https://doi.org/10.1056/nejm200106143442403>
7. Cain N, Irving C, Webber S, Beerman L, Arora G. Natural history of Wolff-Parkinson-White syndrome diagnosed in childhood. *Am J Cardiol*. 2013;112(7):961-965. <https://doi.org/10.1016/j.amjcard.2013.05.035>
8. Wren C, Vogel M, Lord S, et al. Accuracy of algorithms to predict accessory pathway location in children with Wolff-Parkinson-White syndrome. *Heart*. 2012;98(3):202-206. <https://doi.org/10.1136/heartjnl-2011-300269>
9. Boersma L, García-Moran E, Mont L, Brugada J. Accessory pathway localization by QRS polarity in children with Wolff-Parkinson-White syndrome. *J Cardiovasc Electro-physiol*. 2002;13(12):1222-1226. <https://doi.org/10.1046/j.1540-8167.2002.01222.x>
10. Colucci RA, Silver MJ, Shubrook J. Common types of supraventricular tachycardia: diagnosis and management. *Am Fam Physician*. 2010;82(8):942-952. <https://www.aafp.org/afp/2010/1015/p942.html>
11. Keating L, Morris FP, Brady WJ. Electrocardiographic features of Wolff-Parkinson-White syndrome. *Emerg Med J*. 2003;20(5):491-493. <https://doi.org/10.1136/emj.20.5.491>
12. Pappone C, Vicedomini G, Manguso F, et al. Wolff-Parkinson-White syndrome in the era of catheter ablation: insights from a registry study of 2169 patients. *Circulation*. 2014;130(10):811-819. <https://doi.org/10.1161/circulationaha.114.011154>
13. Rao AL, Salerno JC, Asif IM, Drezner JA. Evaluation and management of Wolff-Parkinson-White in athletes. *Sports Health*. 2014;6(4):326-332. <https://doi.org/10.1177/1941738113509059>
14. Richardson JM. Ventricular preexcitation: practical considerations. *Arch Intern Med*. 1983;143(4):760-764. doi:10.1001/archinte.1983.003500401500021
15. Calkins H, Langberg J, Sousa J, et al. Radiofrequency catheter ablation of accessory atrioventricular connections in 250 patients. Abbreviated therapeutic approach to Wolff-Parkinson-White syndrome. *Circulation*. 1992;85(4):1337-1346. <https://doi.org/10.1161/01.cir.1992.85.4.1337>

org/10.1161/01.cir.85.4.1337

16. Crick JC, Davies DW, Holt P, Curry PV, Sowton E. Effect of exercise on ventricular response to atrial fibrillation in Wolff-Parkinson-White syndrome. *Br Heart J*. 1985;54(1):80-85. <https://doi.org/10.1136/hrt.54.1.80>
17. Maron BJ, Zipes DP, Kovacs RJ; American Heart Association Electrocardiography and Arrhythmias Committee of Council on Clinical Cardiology, Council on Cardiovascular Disease in Young, Council on Cardiovascular and Stroke Nursing, Council on Functional Genomics and Translational Biology, and American College of Cardiology. Eligibility and disqualification recommendations for competitive athletes with cardiovascular abnormalities: preamble, principles, and general considerations: a scientific statement from the American Heart Association and American College of Cardiology. *Circulation*. 2015;132(22):e256-e261. <https://doi.org/10.1161/cir.0000000000000236>